



PATIENT PRESENTING CLINICAL SIGNS

Moisha Posh Rescue (Liam)
 History: Moisha (Liam) presented for evaluation of paraplegia.
 Abnormal PE/Chem/CBC/UA Results:

SPECIES COMPUTED TOMOGRAPHIC STUDY OF THE LUMBAR SPINE

Feline A high resolution myelographic CT study of the lumbar spine is provided for review.

BREED COMPUTED TOMOGRAPHIC FINDINGS

DSH Contrast media is seen in subarachnoidal space and the contrast column along the lumbar spine presents an even width without evidence of spinal cord compression.

SEX
 Female The contrast can also be appreciated within the central canal and generalized mild to marked mild irregular saccular widening of the central canal is appreciated, measuring up to 4 mm in diameter is visible – most pronounced level T13/L1 and L3/L4.

COMPUTED TOMOGRAPHIC DIAGNOSIS

AGE
 1.5 Years

- Syringohydromyelia along the lumbar spine

INTERPRETATION OF THE FINDINGS & FURTHER RECOMMENDATIONS

INTERPRETED BY
 Sebastian Schaub, DVM Dr. med. vet. DipECVDI
 There is generalized significant syringohydromyelia of the spinal cord along the lumbar spine. The findings are highly concerning for underlying feline infectious peritonitis with affection of the central nervous system. Complementing workup by a CFS tap including corona virus PCR and antibody titers is recommended. Complementing workup by a CT study of the brain can be beneficial as well to check for hydrocephalus commonly seen in FIP infection. Be aware that negative CNS tap does not rule out potential CNS FIP.

HOSPITAL NAME
 Animal Surgical Center
 Trauma, congenital causes, vascular alterations are potentials causes for syrinx as well.

REFERRING VET

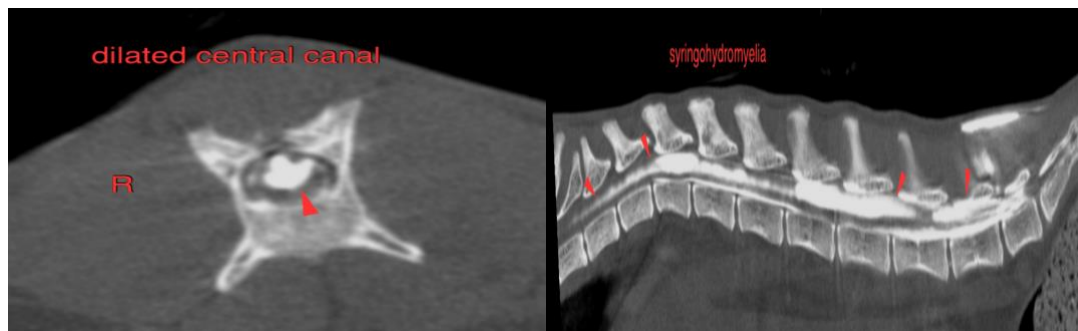
Rescue

INVOICE

13352

DATE

9/29/21





PATIENT

Moisha Posh Rescue
(Liam)

The information and recommendations provided are based on the images presented by the referring veterinarian. No evaluation can be communicated regarding pathology that was not visible in the image/video clips provided.

Thank you for this referral. If the clinical or image interpretation does not parallel your findings or if I can be of any further assistance please contact me.

SPECIES

Feline

Sebastian Schaub, Sebastian Schaub, DVM, Dr. med. vet. DipECVDI
sebast.schaub@gmail.com

BREED

DSH

SEX

Female

AGE

1.5 Years

INTERPRETED BY

Sebastian Schaub,
DVM Dr. med. vet.
DipECVDI

HOSPITAL NAME

Animal Surgical
Center

REFERRING VET

Rescue

INVOICE

13352

DATE

9/29/21